




# Posterior vault distraction osteogenesis: A 10+ years experience.

João Pedro Leite Pereira , Enrico Ghizoni , Cássio Eduardo Raposo Amaral 

<sup>1</sup> Department of Neurology, University of Campinas (UNICAMP), Campinas, São Paulo, Brazil.

<sup>2</sup> Institute of Plastic and Craniofacial Surgery, SOBRAPAR Hospital, Campinas, São Paulo, Brazil

✉ João Pedro Leite Pereira, MD

e-mail: joao.pedro.ip95@gmail.com

Available at:  
<http://www.archpedneurosurg.com.br/>

**Introduction:** Craniosynostosis is a group of diseases whose main characteristic is the premature fusion of one or more cranial sutures. They can be subdivided into non-syndromic and syndromic. The posterior vault distraction osteogenesis (PVDO) has become the standard procedure for managing the intracranial hypertension of these patients. The objective of this paper is to report the experience of the Sobrapar Hospital (Campinas, Brazil) in treating and following up on syndromic craniosynostosis patients subjected to PVDO and highlight the lessons learned throughout this process. **Methods:** The medical records of the patients treated at the Sobrapar Hospital between 2013 and 2023 were reviewed.

**Results:** The total of patients initially candidates to PVDO was 79, and 75 of them proceeded to the surgery. The mean age of surgery was 8,16 months old (ranging from 4 months to 12 years old). The length of stay ranged from 2 to 14 days, with a mean of 3,29 days. The distraction achieved ranged from 13 mm to 30 mm, with a mean distance of 23 mm. The postoperative complications were mostly cutaneous. CSF leak occurred in 3 patients.

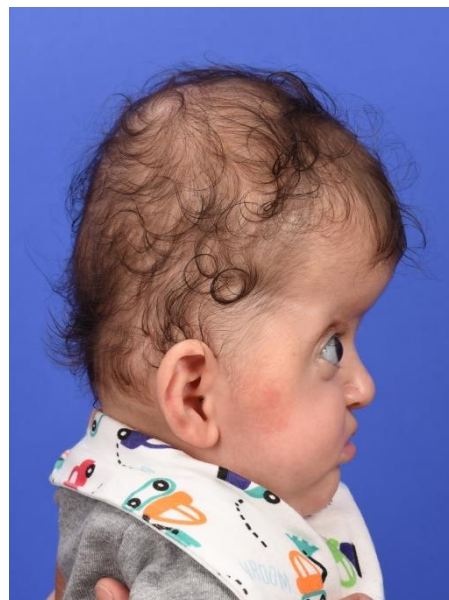**Conclusion:** PVDO provides a progressive formation of a vascularized bone, its intracranial volume expansion is greater than the FOA, increasing the posterior fossa's size (even when the craniotomy is supratentorial) and it improves Chiari's symptoms, even when the radiologic abnormalities are not necessarily solved. A specialized and multidisciplinary team is essential to improving the success rates of the surgery.

Keywords: craniosynostosis, PVDO, distraction osteogenesis, venous hypertension

## INTRODUCTION

Craniosynostosis is a group of diseases whose main characteristic is the premature fusion of one or more cranial sutures, causing the typical phenotype of craniofacial deformities. Depending on which suture is prematurely closed, there are different varieties of cranial shapes and sizes.

They are classified into 2 major groups. The first group is the simple craniosynostosis, where there is only one suture affected. The typical patient is a child with normal neurological development, whose parent's only concern is the cranial deformity, with no other clinical features. The second group is the complex craniosynostosis, where there are two or more sutures affected and a common correlation with intracranial hypertension, hydrocephalus, and venous hypertension. They can be further subdivided into non-syndromic and syndromic, when a genetic syndrome causes not just cranial deformities but also neurological and systemic malformations. (Figure 1). For example, breathing abnormalities (upper airway obstruction retraction of the middle third of the face) and extremities disruptions, such as syndactyly. They make up for about 10% of the craniosynostosis 1, and most of them are begotten by FGFR (fibroblast growth factor receptor) gene mutations 1. The leading syndromes are Apert, Crouzon and Pfeiffer.<sup>1</sup>



**Figure 1-** Classic phenotype of a syndromic craniosynostosis, highlighting brachycephaly, exorbitism and retraction of the middle third of the face.

The main therapeutic objectives of the complex craniosynostosis are airway protection, visual preservation, and intracranial hypertension management. Many medical procedures are necessary to adequately treat these complex patients: tracheostomy and monobloc advancement to



airway protection, tarsorrhaphy, and frontal-orbital advancement to visual preservation, and intracranial volume expansion to decrease intracranial hypertension. Therefore, a deep comprehension of the natural history and treatment algorithms of this particular set of patients is fundamental to ensure that adequate procedures are performed at the adequate time and to safeguard that they won't jeopardize future procedures.<sup>1,2</sup>

The posterior vault distraction osteogenesis (PVDO) has become the standard procedure for managing the intracranial hypertension of syndromic craniosynostosis patients because it enables a major cranial volume gain, decreasing ICP, all the while preserving the frontal bone to allow future procedures, such as monobloc advancement.<sup>1</sup>

The objective of this paper is to report the experience of the Sobrapar Hospital (Campinas, Brazil) in treating and following up on syndromic craniosynostosis patients subjected to posterior vault distraction osteogenesis (PVDO) and highlight the lessons learned throughout this process.

## MATERIALS AND METHODS

### Patient selection

The medical records of the patients treated at the Sobrapar Hospital between 2013 and 2023 were reviewed. The selection criteria were diagnosis of complex craniosynostosis, submitted to PVDO, and minimal post-operative follow-up of six months. The exclusion criteria were refusal to participate in the study.

### Studied variables

Data collected from the medical records included the patient's age during the surgery, gender, millimeters of distraction, post-operative complications, both immediate (CSF leak, hemorrhage) and late (skin alterations), infections, operative time, length of stay, presence of hydrocephalus, shunt presence, post-PVDO shunt need, and presence of trans osseous emissary veins.

### Protocol and surgery technique

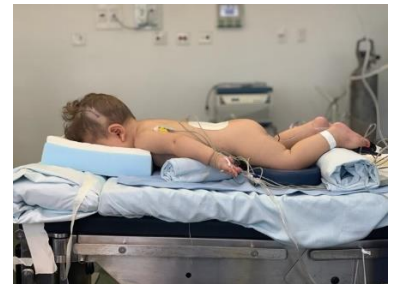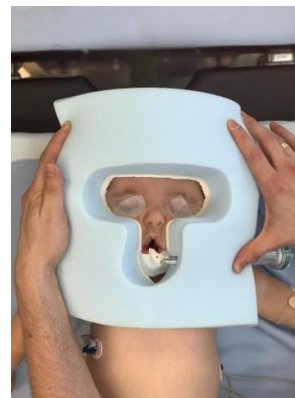Sobrapar Hospital protocol consists of offering PVDO to patients with syndromic craniosynostosis from 6 months old forward, aiming to treat or prevent intracranial hypertension. If signs or symptoms of elevated ICP appear in younger patients (before 6 months old), these patients could be submitted to decompressive craniectomy, suturectomies, or shunt placement, analyzing each case individually.

Whenever possible, the patients are pre-operatively investigated with a vascular exam (venous angio tomography or magnetic resonance venography) to analyze the presence

of trans osseous emissary veins and their relevance to the cerebral venous circulation.

The pre-operative preparation has some particularities. We administer erythropoietin starting three weeks before the surgery, and tranexamic acid is administered during the anesthesia induction to reduce intraoperative bleeding. The orotracheal tube is fixed to a lower arcade tooth using a steel wire to avoid tube displacement since these patients' airway patency is very easily lost.

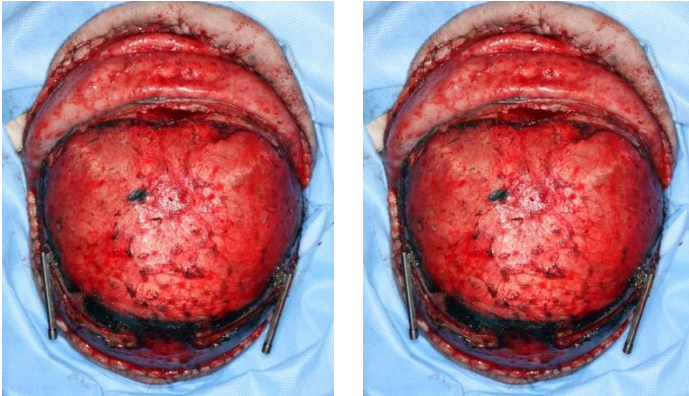
The surgery technique consists in initially positioning the patient in ventral decubitus (Figures 2) and conducting a curvilinear bi-coronal skin incision equidistant to the forehead and to the occiput so that the same incision might be later used for a possible frontal orbital advancement (FOA) or monobloc advancement. We opt to infiltrate the skin with a solution of local anesthetic and epinephrine, aiming to decrease bleeding, aid anesthesia, and smooth the separation between skin and pericranium. We make a suprapariosteal dissection until the torcula, leaving the pericranium stuck to the bone. The craniotomy is parieto-occipital and ample, beginning with two burr holes beside the superior sagittal sinus at the parietal and at the occipital bones, followed by two burr holes at the temporal bone bottom just to the lambdoid suture. After careful dural detachment through the burr holes, the craniotomy is completed.



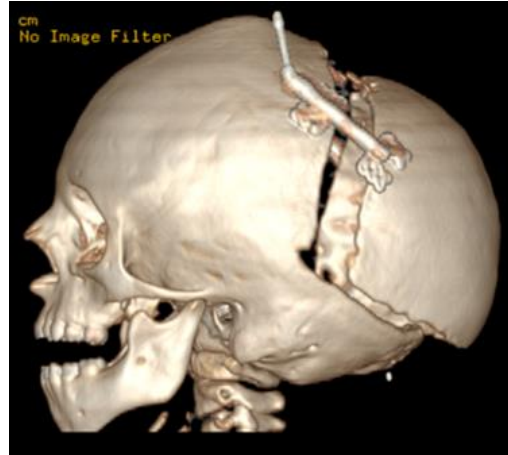
Figures 2 - Patient position in ventral decubitus.

The next step is to close and drape the skin, and turn the patient from ventral to the dorsal decubitus. We believe that this step facilitate a symmetrical distractor placement (parallel to the zygoma) in the craniotomy borders. After fixing the distractors to the bone, we test the instruments and proceed to an initial 1-millimeter distraction, purposing to avoid dead space under the cutaneous flap. As such, we opt not to use any subcutaneous suction drains. (Figures 3 and 4).

Patients are then referred to the pediatric intensive care unit, where they stay for 24 hours of neurological vigilance.



**Figure 3** - Intraoperative PVDO photos showing ample posterior craniotomy and distractor placement.



**Figure 4** - Computerized tomography showing intracranial volume expansion after distraction completion.

Most patients are discharged 48 hours after the surgery, starting the daily 1 millimeter distraction 72 hours after the procedure. The most common distraction goal is at least 25 mm.

## RESULTS

The medical records of the patients treated at the Sobrapar Hospital between 2013 and 2023 were reviewed. The total of patients initially candidates to PVDO was 79, and 75 of them proceeded to the surgery. It must be pointed out that 73 procedures were classic PVDO, and 2 procedures were PVDO with inion zeta-plasty. The remaining 4 patients had FOA performed, due to collateral venous circulation limitations to PVDO (major transosseous emissary veins or sinus pericranii at the craniotomy site).

Regarding the patient population parameters, the mean age of surgery was 8,16 months old (ranging from 4 months to 12 years old), with a mean weight of 7,72 kg. The length of stay ranged from 2 to 14 days, with a mean of 3,29 days. Concerning the total distraction achieved, it ranged from 13 mm to 30 mm, with a mean distance of 23 mm.

The postoperative complications were mostly cutaneous. There were 2 patients with skin necrosis close to the distractor's insertion site, and 1 case of cutaneous infection demanding distractor's removal. CSF leak occurred in 3 patients. One patient was subjected to reoperation and primary dural closure, one patient required ventriculoperitoneal shunt (VPS), and one patient was initially treated with a skin flap, and after 2 months required a ventricular shunt due to hydrocephalus. There was 1 death 14 days after the surgery secondary to pulmonary

complications (bronchoaspiration) in a patient with heart disease.

## DISCUSSION

### *Intracranial hypertension*

Intracranial hypertension is one of the greatest concerns in these patients since it has a deleterious effect in the short, medium, and long terms. It's diagnosed in 47 to 67% of children with syndromic craniosynostosis. The main cause of this phenomenon is the container-content disproportion, secondary to the premature suture fusions. It's also probably relevant to the physiopathology of the skull base foramen stenosis (such as the jugular foramen) and the breathing abnormalities associated with the upper airway obstruction. Other major factors are venous hypertension and hydrocephalus.<sup>1</sup>

It's important to note that the classic signs and signals of intracranial hypertension have low sensitivity in these patients despite a high specificity. For example, papilledema has a sensitivity of 30%, with a specificity of 87%.<sup>1</sup>

The ventriculomegaly is very common, being found in 30-70% of Crouzon and Pfeiffer patients and 40-90% of Apert patients.<sup>1</sup> However, the percentage of hydrocephalus is much lower, varying between 12 to 15% of Apert and Crouzon patients.<sup>1</sup> The ventriculomegaly origin depends on many factors, such as jugular foramen stenosis and chronic tonsillar herniation (type 1 Chiari), which harm the major cerebrospinal fluid (CSF) dynamic pathways.<sup>1</sup> The most common treatment for the hydrocephalus is a ventriculoperitoneal shunt (VPS), but the endoscopic third ventriculostomy (ETV) may be a valid option for some

patients. The moment to treat the hydrocephalus – before or after the cranial volume expansion - is analyzed individually.<sup>1</sup>

### ***Venous hypertension***

Syndromic craniosynostosis are heavily associated with venous hypertension and an abundance of collateral venous circulation through multiple trans osseous emissary veins and sinus pericranii, which are found in 70% of these patients. (Figures 7 and 8). PVDO is a technique performed exactly in the regions where such collateral venous circulation is greater so that the surgeons must be prepared to deal with this particular anatomy and even contraindicate the surgery in situations where the venous manipulation can't be avoided or be safely performed. <sup>3,4,5</sup>

The origin of the venous hypertension is heavily discussed in the scientific literature. It's still unclear if the venous anomalies are secondary, a consequence of intracranial hypertension, working as an additional venous drainage pathway in a context of functional obstruction of the traditional drainage, or if they are primary, being an anatomical variation directly caused by the genetic anomaly, generating jugular foramen and dural sinus stenosis. <sup>3,4,5</sup>

Such is the importance of the venous anatomy that we include a venous vascular exam (venous angio tomography or magnetic resonance venography) as an important piece of the preoperative investigation. <sup>3,5</sup>

The sagittal sinus ratio (SSR) may be used to help ascertain the higher-risk patients candidates for PVDO. This ratio is calculated by dividing the sagittal sinus cross-sectional area after and before a major venous anomaly (great emissary vein or sinus pericranii). (Figures 9 and 10). The lower the ratio, it is implied that the venous anomaly is functionally important to the intracranial outflow; therefore, its surgical manipulation must be avoided. A possible manner to avoid such manipulation is an inion zeta-plasty. (Figures 11 and 12). The candidates pondered as high-risk to PVDO are preferably referred to FOA.

### ***Supratorcular craniotomy***

PVDO craniotomy can be done supratorcular or infratorcular, but we choose the supratorcular one in our hospital since it offers less risk of emissary veins lesions without significant difference in intracranial volume gain and control of Chiari's symptoms. Furthermore, it's key to provide an adequate dural detachment through the burr holes to avoid cerebrospinal fluid leak during the craniotomy. <sup>6</sup>

### ***The use of distractors***

An important notion about the PVDO technique is that it provides a progressive formation of a vascularized bone

since we preserve most of the pericranium over the bone, and most of the dura mater continues attached to the bone (we detach only the dura in the craniotomy route). Besides, the slow distraction allows a progressive adjacent tissue adaptation. The skin closure is also easy since the skin is not tense due to an abrupt intracranial volume gain, as may occur in the surgery techniques that don't use distraction. <sup>2,7,8,9</sup>

The literature shows that PVDO's intracranial volume expansion is greater than the FOA, increasing the posterior fossa's size (even when the craniotomy is supratorcular). Even though the PVDO is a procedure affecting the posterior cranium, there is also some aesthetic improvement in the anterior craniofacial morphology. <sup>2,8,9,10</sup> (Figures 13).

Regarding functional outcomes, PVDO significantly controls intracranial hypertension and tonsillar herniation. A study from Di Rocco et al. highlights that this technique improves Chiari's symptoms, even when the radiologic abnormalities are not necessarily solved. <sup>8,11</sup>

## **CONCLUSIONS**

### ***The multidisciplinary team***

A specialized and diverse team is essential to improving the success rates of the PVDO. Syndromic craniosynostosis patients are very complex, and they must rely on many competent professionals to live fruitful lives. <sup>12,13</sup>

A typical phenotype of these syndromes is the retraction of the middle third of the face, causing upper airway obstruction. Other contributing factors to breathing instability include soft palate thickening, choanal atresia, and tracheal cartilaginous sleeve. The symptoms may vary from mild (such as obstructive sleep apnea, featured in 40-85% of the patients) to severe, with perinatal respiratory failure demanding early tracheostomy. <sup>1,14</sup>

Monobloc advancement may be performed later as a definitive treatment to the middle third retraction of the face. In addition to the aesthetic improvement and intracranial volume expansion, this technique also resolves the upper airway's obstruction. Some patients even become tracheostomy-free after the procedure. <sup>1,15,16</sup>

Syndromic craniosynostosis patients also usually present exorbitism, secondary to a shallow orbital surface. This anatomy predisposes visual loss because of insufficient eyelid closure. Procedures to handle this problem include tarsorrhaphy and frontal-orbital advancement (FOA). <sup>1, 16,17,18</sup>

Thus, a multidisciplinary team is a major factor in our favorable results. Such a team is composed of neurosurgeons, plastic surgeons, anesthesiologists, otorhinolaryngologists, pediatricians, physiotherapists, and

dentists – all of them focused on guaranteeing optimized assistance to our complex, yet incredible little patients.

## DISCLOSURES

### Ethical approval

This study was performed in line with the principles of the Declaration of Helsinki. Approval was granted by the local Ethics Committee, number: Comitê de Ética e Pesquisa da Unicamp: 4.381.031 (Avaliação das nuances neurocirúrgicas em pacientes portadores de craniossinostoses síndrômicas).

### Consent to participate

The patients gave consent to use their information and images for research purposes. *Consent for publication*

The patient gave consent to use his information and images for publication.

### Conflict of interest

The authors report no conflict of interest concerning the materials or methods used in this study or the findings specified in this paper.

### Funding

This research received no specific grant from any funding agency in the public, commercial or not-for-profit sectors

### Artificial intelligence

No artificial intelligence was not used in this paper work

## CONTRIBUTIONS

-**João Pedro Leite Pereira:** Conceptualization, Data curation, Methodology, Writing – original draft

-**Enrico Ghizoni:** Conceptualization, Writing – review & editing

-**Cássio Eduardo Raposo Amaral:** Conceptualization, Data curation, Writing – review & editing

## REFERENCES

1. Tamburrini G, Caldarelli M, Massimi L, Gasparini G, Pelo S, Di Rocco C. (2012). Complex craniosynostoses: a review of the prominent clinical features and the related management strategies. *Childs Nerv Syst* 28:1511–1523.
2. Derderian CA, Wink JD, McGrath JL, Collinsworth A, Bartlett SP, Taylor JA. (2015). Volumetric Changes in Cranial Vault Expansion: Comparison of Fronto-Orbital Advancement and Posterior Cranial Vault Distraction Osteogenesis. *Plastic and Reconstructive Surgery*, Volume 135, Number 6.
3. Thompson DNP, Hayward RD, Harkness WJ, Bingham RM, Jones BM (1995). Lessons from a case of kleeblattschädel Case report. *J. Neurosurg.* Volume 82, June, 1995.
4. Taylor WJ, Hayward RD, Lasjaunias P, Britto JA, Thompson DNP, Jones BM, Evans RD. (2001). Enigma of raised intracranial pressure in patients with complex craniosynostosis: the role of abnormal intracranial venous drainage. *J Neurosurg* 94:377–385.
5. Copeland AE, Hoffmann CE, Tsitouras V, Jeevan DS, Ho ES, Drake JM, Forrest CR. Clinical Significance of Venous Anomalies in Syndromic Craniosynostosis. (2018). *PRS Global Open*.
6. Di Rocco F, Usami K, Protzenko T, Collet C, Giraudat K, Arnaud E. (2018). Results and limits of posterior cranial vault expansion by osteotomy and internal distractors. *Surgical Neurology International* 9:217.
7. Maaten NS, Mazzaferro DM, Wes AM, Naran S, Bartlett SP, Taylor JA. (2018). A Craniometric Analysis of Frontal Cranial Morphology Following Posterior Vault Distraction. *J Craniofac Surg* 00: 00–00.
8. White N, Evans M, Dover MS, Noons P, Solanki G, Nishikawa H. (2008). Posterior calvarial vault expansion using distraction osteogenesis. *Childs Nerv Syst* 25:231–236.
9. Ong J, Harshbarger RJ, Kelley P, George P. (2014). Posterior Cranial Vault Distraction Osteogenesis: Evolution of Technique. *Semin Plast Surg* 28:163–178.
10. Zhang, RS, Wes AM, Naran S, Hoppe IC, Sun J, Mazzaferro D, Bartlett SP, Taylor JA. (2018). Posterior Vault Distraction Osteogenesis in Nonsyndromic Patients: An Evaluation of Indications and Safety. *J Craniofac Surg* 2018;00: 00–00.
11. Levitt MR, Niazi TN, Hopper RA, Ellenbogen RG, Ojemann JG. (2012). Resolution of syndromic craniosynostosis-associated Chiari malformation Type I without suboccipital decompression after posterior cranial vault release. *J Neurosurg: Pediatrics*, Volume 9, February 2012.
12. Raposo-Amaral CE, de Oliveira YM, Denadai R, Raposo-Amaral CA, Ghizoni E (2021) Syndrome-related outcomes following posterior vault distraction osteogenesis. *Child's nervous system : ChNS : official journal of the International Society for Pediatric Neurosurgery* 37:2001-2009. doi:10.1007/s00381-021-05169-w
13. Raposo-Amaral CE, Denadai R, Maximo G, Raposo-Amaral CA, Ghizoni E (2020) Pfeiffer Syndrome: A Therapeutic Algorithm Based on a Modified Grading Scale. *Plastic and reconstructive surgery Global open* 8:e2788. doi:10.1097/GOX.0000000000002788

## Distraction osteogenesis in craniosynostosis: technical note

14. Raposo-Amaral CE, Denadai R, Oliveira YM, Ghizoni E, Raposo-Amaral CA (2020) Apert Syndrome Management: Changing Treatment Algorithm. *The Journal of craniofacial surgery* 31:648-652. doi:10.1097/SCS.0000000000006105
15. Raposo-Amaral CE, Menezes PT, Gil A, Raposo-Amaral CA, Ghizoni E (2022) Behavioral, Learning Skills, and Visual Improvement in Crouzon Syndrome Patient Following Late Posterior Vault Distraction Osteogenesis. *The Journal of craniofacial surgery* 33:2589-2592. doi:10.1097/SCS.0000000000008954
16. Raposo-Amaral CE, Oliveira YM, Raposo-Amaral CA, Ghizoni E (2022) Apert Syndrome Outcomes: Comparison of Posterior Vault Distraction Osteogenesis Versus Fronto Orbital Advancement. *The Journal of craniofacial surgery* 33:66-69. doi:10.1097/SCS.0000000000007959
17. Raposo-Amaral CE, Raposo-Amaral CA, Adams JW, Ghizoni E (2022) Posterior Vault Distraction Outcomes in Patients With Severe Crouzon Syndrome Resulting from Ser347Cys and Ser354Cys Mutations. *The Journal of craniofacial surgery* 33:1545-1548. doi:10.1097/SCS.0000000000008642
18. Raposo-Amaral CE, Vincenzi-Lemes M, Medeiros ML, Raposo-Amaral CA, Ghizoni E (2024) Apert syndrome: neurosurgical outcomes and complications following posterior vault distraction osteogenesis. *Child's nervous system: ChNS :official journal of the International Society for Pediatric Neurosurgery*. doi:10.1007/s00381-024-06436-2